



# Eosinophilic Myeloproliferative Disorders

Amy D. Klion<sup>1</sup>

<sup>1</sup>National Institute of Allergy and Infectious Diseases, National Institutes of Health, Bethesda, MD

Despite recent attempts to define and classify patients with marked eosinophilia and features consistent with myeloproliferative disease, areas of controversy remain. These are particularly apparent in situations in which multiple lineages are involved in a clonal process and clinical manifestations are overlapping. Although the introduction of new molecular diagnostics and targeted therapies has begun to clarify the boundaries between some of these disorders, several questions remain with respect to the classification of patients with myeloproliferative hypereosinophilic syndrome (HES) of unknown etiology.

## Introduction: history

Hypereosinophilic syndrome (HES) was first recognized as a distinct clinical entity in 1975, when Chusid et al<sup>1</sup> proposed the following definition: (1) a persistent eosinophilia of  $1.5 \times 10^9/\text{L}$  eosinophils/ $\text{mm}^3$  for longer than 6 months or death before 6 months associated with the signs and symptoms of hypereosinophilic disease; (2) a lack of evidence for parasitic, allergic, or other known causes of eosinophilia; and (3) presumptive signs and symptoms of organ involvement, including hepatosplenomegaly, organic heart murmur, congestive heart failure, diffuse or focal nervous system abnormalities, pulmonary fibrosis, fever, weight loss, and anemia. Even then, it was recognized that these criteria encompassed a wide variety of disorders, with chronic eosinophilic leukemia (CEL) at one end of the spectrum. In fact, nearly 1/3 of the cases described in this landmark paper had detectable myeloblasts in the peripheral blood, and 4 of 18 subjects had abnormal cytogenetics.

More recently, the availability of molecular and immunologic diagnostic techniques and targeted therapies has led to the identification of specific etiologies in some patients with HES. This has caused considerable controversy, particularly with respect to the subset of eosinophilic patients with evidence of chronic myeloproliferative disease. Whereas the 2001 World Health Organization (WHO)<sup>2</sup> classification lumped all patients with CEL or HES into a single diagnosis under the category of chronic myeloproliferative diseases, the new WHO classification separates these patients into 2 groups: CEL not otherwise categorized (CEL-NOS) and myeloid neoplasms associated with eosinophilia and abnormalities of *PDGFRA*, *PDGFRB*, and *FGFR1*<sup>2</sup> (Table 1). CEL-NOS is listed in the category of myeloproliferative neoplasms, whereas the second group is a new category. Patients with HES and myeloproliferative features who do not have detectable mutations or evidence of clonality are not included in the 2008 classification scheme. Although this classification makes sense in some respects, including the recognition that *D816VKIT*-positive systemic mastocytosis (SM) is a disorder that is distinct from *PDGFRA*-associated myeloid neoplasms, it is confusing from a clinical diagnostic and treatment standpoint because there is considerable overlap between the clinical and hematologic manifestations of CEL-NOS, *PDGFRA*-associated disease, and those of patients with HES who have myeloproliferative features but in whom clonality cannot be proven.

An alternative classification scheme, proposed by the Hypereosinophilic Diseases Working Group of the International Eosinophil Society in 2006<sup>4</sup> and revised at a subsequent workshop in 2010,<sup>5</sup>

attempted to incorporate both clinical and molecular features (Table 1). Patients presenting with HES with clinical, laboratory, and BM features consistent with a myeloproliferative disorder were grouped under the heading “myeloproliferative forms.” This category was divided into CEL and myeloproliferative HES based on the presence of eosinophil clonality as demonstrated by molecular tests, cytogenetics, HUMARA assay, or the presence of increased blasts. The purpose of this classification scheme was 2-fold: (1) to emphasize that patients with myeloproliferative features with or without demonstrable eosinophil clonality are more similar to each other than to other patients with HES and (2) to minimize the need for reclassification of patients as new molecular abnormalities are defined. Myeloid neoplasms, including those associated with *FGFR1* and *KIT*, were included in a separate category called “associated” to indicate that marked eosinophilia can be present, but that the predominant clinical features are due to involvement of lineages other than eosinophils.

Regardless of the classification system used, it is clear that these disorders are rare. In fact, a recent study using the Surveillance, Epidemiology and End Results (SEER) database calculated the crude incidence of HES including CEL (under the general category of chronic myeloproliferative disorders) at 0.036 in 100 000 person-years.<sup>6</sup> This has further complicated efforts to draw general conclusions about clinical manifestations, responses to treatment, and prognosis in affected patients.

This review describes 3 distinct WHO-defined disorders for which the clinical and/or hematologic presentations overlap with HES and discuss the relationship of these disorders to “myeloproliferative HES.” Myeloid neoplasms with abnormalities of *PDGFRB*, *FGFR1*, and *JAK2* will not be discussed herein, because these disorders rarely present as HES despite the presence of peripheral and/or BM eosinophilia.

## Myeloproliferative HES

A subgroup of patients with eosinophilia  $> 1.5 \times 10^9/\text{L}$ , features of myeloproliferative disease, and poor prognosis has long been recognized.<sup>7</sup> In fact, almost 50% (33 of 72) of patients who met Chusid's criteria for HES in 2 separate series reported in the early 1980s were found to exhibit features of a myeloproliferative disorder, including hypercellularity of the BM, abnormalities in cell lineages other than eosinophils, myelofibrosis, splenomegaly, and elevated serum B12 levels.<sup>8,9</sup> These patients were less likely to respond to steroid therapy, had more aggressive disease, and

**Table 1. Classification of eosinophilic myeloproliferative neoplasms**

WHO 2001 <sup>2</sup>	WHO 2008 <sup>3</sup>	HES Working Group <sup>4,5</sup>
CMD	MPN	Myeloproliferative HES
CEL (and HES)	CEL-NOS	PDGFRA-associated CEL
CMML	Mastocytosis	CEL-NOS
CMML with eosinophilia	MPN, unclassifiable	HES with myeloproliferative features but clonality unproven
Mastocytosis	Myeloid and lymphoid neoplasms associated with eosinophilia and abnormalities of PDGFRA, PDGFRB or FGFR1	Associated HES
SM-eo		SM-eo

CMD indicates chronic myeloproliferative disease; CMML, chronic myelomonocytic leukemia; and MPN, myeloproliferative neoplasm.

included 8 patients with detectable cytogenetic abnormalities (CEL-NOS). More recently, myeloproliferative features in the setting of marked eosinophilia and clinical manifestations of HES have been associated with the presence of the *FIP1L1/PDGFR*A fusion gene.<sup>10</sup>

Although it is clear that CEL-NOS- and *PDGFRA*-associated disease account for a significant proportion of the cases of HES with myeloproliferative features, a causative genetic abnormality cannot be demonstrated in all cases. In a French series of 35 patients with HES, 9 patients were described as having clinical or hematological features of myeloproliferative syndrome (including palpable splenomegaly, neutrophilia, circulating myelocytes and/or erythroblasts, hyperplastic BM, and myelofibrosis).<sup>11</sup> Three of the 9 patients had no detectable *FIP1L1/PDGFR*A (F/P) fusion gene or cytogenetic abnormalities, and 1 responded to imatinib therapy. Several additional case series have described imatinib-responsive, F/P-negative patients with HES,<sup>12-15</sup> although the presence of myeloproliferative features in these patients has not been systematically addressed.

Therefore, despite early data suggesting that HES with myeloproliferative features has an aggressive course and poor prognosis, it is unclear whether this is the case when patients with cytogenetic abnormalities and mutations in *PDGFRA* are excluded. Whether these patients should be classified separately from other patients with “idiopathic HES” and/or managed differently remains controversial.

**PDGFRA-associated disease**

Myeloid neoplasms associated with eosinophilia and abnormalities of *PDGFRA* account for approximately 10%-20% of patients presenting with clinical findings consistent with HES. First described in a patient with imatinib-responsive HES and a t(1;4)(q44;q12) translocation,<sup>13</sup> the F/P fusion gene is the most common abnormality and arises from an 800-kb interstitial deletion, del(4)(q12q12), that leads to constitutive activation of *PDGFRA*. The break points in *FIP1L1* are variable, but are typically located in a 40-kb region spanning introns 7-10 of *FIP1L1*. In contrast, the break points in *PDGFRA* appear to be restricted to a region of exon 12 that contains the WW-like region of the juxtamembrane domain. Although some patients with F/P have a reciprocal translocation in 4q12, most have a normal karyotype. More recently, several additional *PDGFRA* fusion partners have been identified, including KIF5B,<sup>16</sup> CDK5RAP2,<sup>17</sup> STRN,<sup>18</sup> BCR, and ETV6.<sup>18</sup> Although point mutations in *PDGFRA* have been detected in patients with HES and have been shown to cause growth factor-independent proliferation in vitro and leukemia-like disease in mice, their role in disease pathogenesis in humans is unproven.<sup>19</sup>

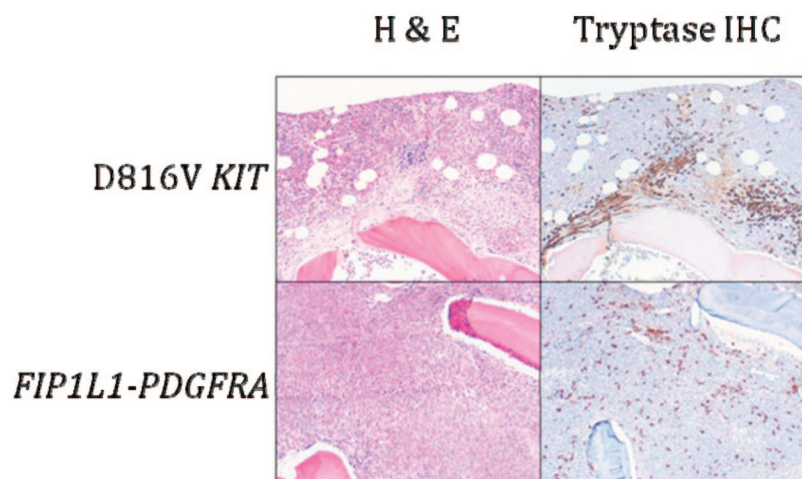
**Clinical and laboratory features**

The overwhelming majority of patients with *PDGFRA*-associated myeloid neoplasms are male, although the reason for this gender bias is unknown. Whereas most patients are between 20 and 40 years of age, the F/P fusion has been described in children as young as 3 months<sup>20</sup> and in the elderly. End-organ manifestations are similar to those seen in classic HES, although splenomegaly and fibrotic complications, including endomyocardial fibrosis, restrictive pulmonary disease, and myelofibrosis, seem to be more frequent in patients with the F/P mutation.<sup>10-12,21</sup> Unusual skin manifestations, including lymphomatoid papulosis<sup>22,23</sup> and mucosal ulcerations,<sup>10,24</sup> have also been reported. Before the availability of imatinib, prognosis for patients with *PDGFRA*-associated eosinophilic disorders was poor, with a 30%-50% mortality at 5 years, primarily due to cardiac and neurologic complications.<sup>10,21</sup>

As in other myeloid neoplasms, multiple lineages can be involved in the clonal process.<sup>25</sup> Despite this, proliferation is generally restricted to eosinophils, mast cells, and in approximately 50% of cases, neutrophils. T-cell clones,<sup>26,27</sup> as well as synchronous T-cell lymphoblastic lymphoma,<sup>28</sup> have been described in patients with F/P-positive myeloid neoplasms, although this appears to be a rare phenomenon. Laboratory abnormalities other than leukocytosis that are commonly seen in *PDGFRA*-associated myeloid neoplasms include anemia, thrombocytopenia, and elevated serum B12 and tryptase levels.<sup>10,11,21</sup> Serum IgE elevation is variable. BM examination typically reveals a hypercellular BM with marked eosinophilia and increased numbers of scattered, spindle-shaped, CD25<sup>+</sup> mast cells without dense focal infiltrates<sup>29</sup> (Figure 1). Reticulin fibrosis is often increased.

**Diagnosis**

The F/P mutation can be detected by RT-PCR or FISH.<sup>13</sup> Although a formal comparison study has not been performed to date, there does not seem to be a difference in sensitivity or specificity between the 2 methods, and the fusion can be detected equally well in peripheral blood and BM aspirates. Other *PDGFRA* fusions described to date have been associated with translocations and can be detected with routine cytogenetic analysis. Despite overlap between the diagnostic criteria for SM (see below) and the characteristic features of *PDGFRA*-associated myeloid neoplasms, it is important to distinguish between these 2 disorders because there are differences in clinical manifestations, response to therapy, and prognosis. Although demonstration of a D816V mutation in *KIT* or a *PDGFRA* fusion gene is clearly the “gold standard” for diagnosis, SM and *PDGFRA*-associated myeloid neoplasms can also be differentiated using a clinical scoring system (Table 2).<sup>29</sup>



**Figure 1.** BM histopathology in D816V *KIT*-positive SM with eosinophilia (D816V *KIT*) and *PDGFRA*-positive myeloid neoplasia (*FIP1L1-PDGFRA*). Sections were stained with H&E or anti-tryptase antibody. Dense aggregates containing > 15 mast cells are seen in D816V *KIT*-positive SM with eosinophilia, whereas scattered spindle-shaped mast cells forming loose collections are typical of *PDGFRA*-positive myeloid neoplasia. Magnification is 100 $\times$ .

### Treatment and monitoring

Imatinib is the treatment of choice for patients with *PDGFRA*-positive disease, and the majority of patients achieve clinical and hematologic improvement within 2-4 weeks and molecular remission within 3-6 months. Although most clinical manifestations improve with imatinib treatment, structural damage, including cardiac valve abnormalities and ischemic injury, are permanent. Therefore, imatinib treatment should be initiated as soon as possible after the diagnosis is made.

Although there is some controversy as to the most appropriate starting dose (100-400 mg daily) of imatinib, it is clear that most patients can be maintained successfully on low doses (100 mg daily to 100 mg weekly) once remission is achieved.<sup>30</sup> Side effects of therapy are similar to those seen in the treatment of chronic myeloid leukemia (CML), with the exception of acute cardiac decompensation, which has been described after imatinib treatment of HES in patients with known cardiac involvement and/or an elevated serum troponin.<sup>31</sup> Administration of corticosteroids for several days before the initiation of imatinib therapy and for several days thereafter has been recommended, although there are no data to confirm that this will prevent complications in patients with preexisting eosinophilic infiltration of the heart, and myocardial necrosis has occurred after initiation of imatinib therapy in at least one patient despite high-dose steroids.<sup>32</sup> Imatinib-induced cardiac toxicity independent

of eosinophilia was demonstrated in vitro, in a murine model, and in a cohort of 10 patients with CML,<sup>33</sup> but has not been confirmed in subsequent retrospective and prospective studies.<sup>34-36</sup>

To date, there have been no reports of cure with imatinib, although patients may remain in remission for several months after interruption of therapy.<sup>37</sup> Although the optimal frequency of hematologic and molecular monitoring once a stable dose of imatinib has been reached is unknown, it seems reasonable to perform a complete blood count every 3 months and molecular testing every 6 months in the absence of clinical signs suggestive of relapse. Screening for occult end organ involvement and/or evidence of drug toxicity, including clinical examination, routine chemistries, echocardiography, and pulmonary function testing, should also be performed every 6 months.

A single case of primary resistance to imatinib has been reported<sup>38</sup> and secondary resistance appears to be rare, with only 7 cases reported in the literature to date.<sup>13,16,39-43</sup> Most cases have been due to the appearance of a T674I mutation that is homologous to the T315I mutation that confers resistance to imatinib in CML, and recent data suggest that the low incidence of resistance may be due to a limited repertoire of possible mutations affecting the *PDGFRA* kinase domain.<sup>44</sup> Second-line tyrosine kinase inhibitors, including nilotinib, sorafenib, and dasatinib, have in vitro activity against F/P,

**Table 2.** Clinical scoring system used to distinguish D816V *KIT*-positive SM from *PDGFRA*-positive myeloid neoplasia\*

Score	Risk factor for <i>FIP1L1/PDGFRA</i> eosinophilia	Score	Risk factor for <i>KIT</i> D816V eosinophilia
+3	AEC/tryptase > 100	-3	AEC/tryptase $\leq$ 100
+3	Dense mast cell aggregates in BM absent	-3	Dense mast cell aggregates in BM present
+3	Peak AEC > 10 000		
+2	Serum B12 elevated	-2	Gastrointestinal symptoms
		-2	Urticaria pigmentosa
+1	Pulmonary symptoms	-1	Female gender
+1	Cardiac symptoms	-1	Thrombocytosis

AEC indicates absolute eosinophil count.

\*Positive total denotes *FIP1L1/PDGFRA* CEL; negative total denotes *KIT* D816V-positive SM with eosinophilia. Determine the total score after considering risk factors in both columns.



**Table 3. WHO diagnostic criteria for systemic mastocytosis**

<b>Major criterion</b>
Multifocal dense infiltrates of mast cells in BM or other extracutaneous organ
<b>Minor criteria</b>
> 25% of mast cells in BM or noncutaneous tissue biopsy sections with spindle-shaped or atypical morphology
Mast cells in the BM, blood, or lesional tissue expressing CD25 and/or CD2
Detection of a codon 816 c-kit point mutation in blood, BM, or lesional tissue
Serum tryptase level persistently > 20 ng/mL

and nilotinib has been used successfully in one patient with imatinib resistant disease in the absence of a definable point mutation.<sup>43</sup> Unfortunately, treatment of patients with imatinib resistance due to the T674I mutation has been ineffective to date, despite the availability of agents, such as sorafenib, that are effective against this mutation in vitro. In one case, outgrowth of a new pan-resistant clone after sorafenib treatment was the cause of the treatment failure.<sup>40</sup> Nonmyeloablative allogeneic transplantation has been used successfully in HES<sup>45</sup> and remains an option for the treatment of aggressive disease unresponsive to tyrosine kinase inhibitors.

### CEL-NOS

CEL-NOS is the name given to unexplained eosinophilia  $> 1.5 \times 10^9/L$  in the presence of  $> 2\%$  peripheral blood or  $> 5\%$  BM blasts, clonal eosinophils, or abnormal cytogenetics. To make a diagnosis of CEL-NOS, other myeloid neoplasms, clonal or phenotypically aberrant T cells, *BCR/ABL*, and abnormalities in *PDGFRA*, *PDGFRB*, and *FGFR1* must be excluded. A variety of chromosomal abnormalities have been described in CEL-NOS, the most common of which is trisomy 8.<sup>46</sup> Eosinophil clonality has also been demonstrated in the absence of cytogenetic abnormalities by HUMARA analysis in one female patient presenting with HES.<sup>47</sup> Cases of CEL-NOS are exceedingly rare, but tend to be aggressive and unresponsive to therapy. IFN- $\alpha$  has been used successfully in a small number of cases, both alone<sup>48,49</sup> and in combination with other agents.<sup>50</sup> A short trial of imatinib 400 mg/d is also reasonable given the favorable side-effect profile, although the few cases of CEL-NOS treated with imatinib reported in the literature have been unresponsive. Finally, BM transplantation remains an option for CEL-NOS and should be considered early given the poor prognosis despite chemotherapy in most cases.

### SM with eosinophilia

SM is a rare disorder characterized by an increased number of mast cells in the BM and/or other extracutaneous organs. The current WHO definition of SM requires the presence of 1 major + 1 minor criterion or 3 minor criteria (Table 3) and separates SM into disease variants based on the mast cell burden, involvement of non-mast cell lineages, and disease aggressiveness.<sup>3,51</sup> The activating *KIT* mutation D816V is present in BM cells of 70%-93% of patients with SM,<sup>51,52</sup> but is rarely detectable in the peripheral blood except in cases of mast cell leukemia. Other *KIT* mutations have been reported in SM, but are uncommon, representing  $< 3\%$  of detectable abnormalities.<sup>51,52</sup> Although SM with associated clonal hematological non-MC-lineage disease is a well-recognized SM variant, D816V *KIT* and F/P have not been detected in the same person to date.

### Clinical and laboratory features

SM can occur at any age and is equally frequent in men and women. The clinical presentation is very variable, ranging from isolated BM involvement with minimal symptoms to rapidly fatal mast cell leukemia. Signs and symptoms are related to mast cell infiltration of tissues and mediator release, and classically include urticaria pigmentosa, flushing, abdominal pain, diarrhea, hepatosplenomegaly, lymphadenopathy, and bone pain. Constitutional symptoms, including fatigue, weight loss, fever, and night sweats are common, and anaphylaxis was seen in  $> 50\%$  of patients in some series.<sup>53</sup>

Serum tryptase levels are elevated in nearly all patients with SM and are correlated with total mast cell burden.<sup>54</sup> Additional laboratory abnormalities include anemia, thrombocytopenia, hypoalbuminemia, and elevated transaminases.<sup>55</sup> BM examination typically shows a hypercellular BM with focal, dense, paratrabecular aggregates of atypical spindle-shaped mast cells and increased numbers of eosinophils and lymphocytes.<sup>56</sup> Osteolytic or osteosclerotic changes in the bone trabeculae may accompany mast cell infiltration, and myelofibrosis is common, especially in advanced disease. Expression of CD25 and/or CD2 on CD117 (*KIT*)-positive mast cells can be demonstrated by immunohistochemistry or flow cytometry.<sup>51</sup>

Peripheral blood eosinophilia  $> 1.5 \times 10^9/L$  is found in  $\sim 15\%$  of patients with F/P-negative SM<sup>29,55</sup> and up to 50% of patients with D816V *KIT*-positive mast cell leukemia.<sup>52</sup> This is likely due to the presence of the mutation in myeloid precursors. In fact, several studies have demonstrated decreased survival in patients with D816V *KIT*-positive SM and concomitant eosinophilia,<sup>57</sup> perhaps due to clonal involvement at an earlier stage of myelopoiesis. Interestingly, however, the D816V *KIT* mutation was identified in both eosinophils and CD34<sup>+</sup> hematopoietic stem cells in 30% of patients with mutation-positive SM, regardless of whether peripheral eosinophilia was present.<sup>52</sup>

### Diagnosis

Diagnosis of SM requires careful morphologic and immunohistochemical analysis of the BM by an experienced pathologist. In addition, the presence of D816V *KIT* should be assessed in BM by RT-PCR with restriction fragment length polymorphism, peptide nucleic acid-mediated PCR, or allele-specific PCR.<sup>51</sup> In the absence of a detectable D816V mutation and aggressive disease, additional analyses for mutations in *KIT* or other abnormalities should be performed, because the results may have therapeutic implications. As previously discussed, patients with peripheral eosinophilia  $> 1.5 \times 10^9/L$  and BM mastocytosis present a unique diagnostic challenge due to overlapping clinical manifestations and BM findings in D816V *KIT*-positive SM and *PDGFRA*-associated myeloid neoplasms.<sup>52</sup>

### Treatment

The treatment of patients with SM can be frustrating, because there is no curative therapy and no single agent has demonstrated success in a majority of patients. Treatment of indolent or smoldering SM is generally directed at reducing clinical symptoms. For more aggressive disease, several agents have been tried, with varying results. In a recent study examining the efficacy of chemotherapy in 108 F/P-negative patients with SM,<sup>58</sup> response rates ranged from  $< 20\%$  for imatinib and hydroxyurea to 53% and 55% for IFN- $\alpha$  and 2-chlorodeoxyadenosine, respectively. Complete responses were seen in only 2 patients, one who received IFN- $\alpha$  and

one who was treated with 2-chlorodeoxyadenosine. The lack of response to imatinib is consistent with in vitro data demonstrating resistance of the D816V *KIT* mutation to imatinib therapy.<sup>59</sup> It should be noted, however, that rare cases of SM with atypical *KIT* mutations have been shown to respond to imatinib.<sup>60,61</sup> Dasatinib showed slightly better efficacy than imatinib in one trial.<sup>62</sup> Newer agents, including PKC412, AMN107, and 17-AAG, have in vitro activity, but data on clinical efficacy are lacking. BM transplantation has been attempted in patients with advanced disease refractory to therapy, with discouraging results.<sup>63</sup>

## Conclusions

Molecular diagnostics and targeted therapeutics are beginning to provide the necessary tools with which to reliably distinguish between the different myeloproliferative disorders associated with eosinophilia, including PDGFRA-associated myeloid neoplasms, CEL-NOS, and SM with peripheral eosinophilia. This has complicated the interpretation of results from prior clinical studies in which patients with disorders of differing etiologies were grouped together for analysis. As additional molecular markers are discovered and new subgroups of myeloproliferative HES are delineated, existing descriptions of clinical manifestations, prognosis, and response to treatment will need to be modified.

## Disclosures

Conflict-of-interest disclosure: The author declares no competing financial interests. Off-label drug use: prednisone, hydroxyurea, IFN, mepolizumab, reslizumab, dasatinib, nilotinib, and sorafenib were all used off-label for the treatment of myeloproliferative HES.

## Correspondence

Amy D. Klion, Laboratory of Parasitic Diseases, National Institute of Allergy and Infectious Diseases, National Institutes of Health, Building 50/Room 6351, 50 South Dr, Bethesda, MD 20892; Phone: (301) 435-8903; Fax: (301) 451-2029; e-mail: aklion@niaid.nih.gov.

## References

- Chusid MJ, Dale DC, West BC, Wolff SM. The hypereosinophilic syndrome: analysis of fourteen cases with review of the literature. *Medicine*. 1975;54:1-27.
- Jaffe ES, Harris NL, Stein H, eds. International Agency for Research on Cancer. *WHO Classification of Tumors of Haematopoietic and Lymphoid Tissue* (3rd ed). Lyon, France; World Health Organization, 2001.
- Swerdlow S, Campo E, Harris NL, eds.; International Agency for Research on Cancer. *WHO Classification of Tumours of Haematopoietic and Lymphoid Tissue*. Lyon, France: World Health Organization; 2008.
- Klion AD, Bochner BS, Gleich GJ, et al. Approaches to the treatment of hypereosinophilic syndromes: a workshop summary report. *J Allergy Clin Immunol*. 2006;117:1292-1302.
- Simon HU, Rothenberg ME, Bochner BS et al. Redefining the definition of hypereosinophilic syndrome. *J Allergy Clin Immunol*. 2010;126:45-49.
- Crane MM, Chang CM, Kobayashi MG, Weller PF. Incidence of myeloproliferative hypereosinophilic syndrome in the United States and an estimate of all hypereosinophilic syndrome incidence. *J Allergy Clin Immunol*. 2010;126:179-181.
- Weller PF, Bubley GJ. The idiopathic hypereosinophilic syndrome. *Blood*. 1994;83:2759-2779.
- Flaum MA, Schooley RT, Fauci AS, Gralnick HR. A clinicopathologic correlation of the idiopathic hypereosinophilic syndrome. I. Hematologic manifestations. *Blood*. 1981;58:1012-1020.
- Lefebvre C, Bletry O, Degoulet P, et al. Prognostic factors of hypereosinophilic syndrome. Study of 40 cases [Article in French]. *Ann Med Interne (Paris)*. 1989;140:253-257.
- Klion AD, Noel P, Akin C, et al. Elevated serum tryptase levels identify a subset of patients with a myeloproliferative variant of idiopathic hypereosinophilic syndrome associated with tissue fibrosis, poor prognosis and imatinib-responsiveness. *Blood*. 2003;101:4660-4666.
- Roche-Lestienne C, Lepers S, Soenen-Cornu V, et al. Molecular characterization of the idiopathic hypereosinophilic syndrome (HES) in 35 French patients with normal conventional cytogenetics. *Leukemia*. 2005;19:792-798.
- Baccarani M, Cilloni D, Rondoni M, et al. The efficacy of imatinib mesylate in patients with *FIP1L1-PDGFR* alpha-positive hypereosinophilic syndrome. Results of a multicenter prospective study. *Haematologica*. 2007;92:1173-1179.
- Cools J, DeAngelo DJ, Gotlib J, et al. A novel tyrosine kinase created by the fusion of the *PDGFRA* and *FIP1L1* genes is a therapeutic target of imatinib in idiopathic hypereosinophilic syndrome. *N Engl J Med*. 2003;348:1201-1214.
- Metzgeroth G, Walz C, Erben P, et al. Safety and efficacy of imatinib in chronic eosinophilic leukemia and hypereosinophilic syndrome—a phase II study. *Br J Haematol*. 2008;143:707-715.
- Ogbogu PO, Bochner BS, Butterfield JH, et al. Hypereosinophilic syndromes: a multicenter, retrospective analysis of clinical characteristics and response to therapy. *J Allergy Clin Immunol*. 2009;124(6):1319-1325.e3.
- Score J, Walz C, Jovanovic JV, et al. Detection and molecular monitoring of *FIP1L1-PDGFR*-positive disease by analysis of patient-specific genomic DNA fusion junctions. *Leukemia*. 2009;23:332-339.
- Walz C, Curtis CE, Schnittger S, et al. Transient response to imatinib in a chronic eosinophilic leukemia associated with ins(9;4)(q33;q12q25) and a *CDK5RAP2-PDGFR* fusion gene. *Genes Chromosomes Cancer*. 2006;45:950-956.
- Curtis CE, Grand FH, Musto P, et al. Two novel imatinib-responsive PDGFRA fusion genes in chronic eosinophilic leukemia. *Br J Haematol*. 2007;138:77-81.
- Elling C, Erben P, Walz C, et al. Novel imatinib-sensitive PDGFRA-activating point mutations in hypereosinophilic syndrome induce growth factor independence and leukemia-like disease. *Blood*. 2011;117:2935-2943.
- Rathe M, Kristensen TK, Moller MB, Carlsen NL. Myeloid neoplasm with prominent eosinophilia and PDGFRA rearrangement treated with imatinib mesylate. *Pediatr Blood Cancer*. 2010;55:730-732.
- Vandenberghe P, Wlodarska I, Michaux L, et al. Clinical and molecular features of *FIP1L1/PDGFR*(+) chronic eosinophilic leukemias. *Leukemia*. 2004;18:734-742.
- McPherson T, Cowen EW, McBurney E, Klion AD. Platelet-derived growth factor receptor-alpha-associated hypereosinophilic syndrome and lymphomatoid papulosis. *Br J Dermatol*. 2006;155:824-826.
- Thuny C, Gaudy-Marqueste C, Nicol I, et al. Chronic eosinophilic leukaemia revealed by lymphomatoid papulosis: the role of the *FIP*-like 1-platelet-derived growth factor receptor alpha fusion gene. *J Eur Acad Dermatol Venereol*. 2010;24:234-235.
- Leiferman KM, Gleich GJ. Hypereosinophilic syndrome: case presentation and update. *J Allergy Clin Immunol*. 2004;113:50-58.

25. Robyn J, Lemery S, McCoy JP, et al. Multilineage involvement of the fusion gene in patients with *FIPILI/PDGFR*-positive hypereosinophilic syndrome. *Br J Haematol.* 2006;132:286-292.
26. Burbury K, Chew LP, Westerman D, Catalano A, Seymour JF. Concomitant *FIPILI-PDGFR* fusion gene and T cell clonality in a case of chronic eosinophilic leukemia with clonal evolution and incomplete response to imatinib. *Leuk Lymphoma.* 2011;52:335-338.
27. Helbig G, Wieczorkiewicz A, Dziaczkowska-Suszek J, Majewski M, Kyrz-Krzemien S. T-cell abnormalities are present at high frequencies in patients with hypereosinophilic syndrome. *Haematologica.* 2009;94:1236-1241.
28. Capovilla M, Cayuela JM, Bilhou-Nabera C, et al. Synchronous *FIPILI-PDGFR*-positive chronic eosinophilic leukemia and T-cell lymphoblastic lymphoma: a bilineal clonal malignancy. *Eur J Haematol.* 2008;80:81-86.
29. Maric I, Robyn J, Metcalfe DD, et al. *KIT* D816V-associated systemic mastocytosis with eosinophilia and *FIPILI/PDGFR*-associated chronic eosinophilic leukemia are distinct entities. *J Allergy Clin Immunol.* 2007;120:680-687.
30. Helbig G, Stella-Holowiecka B, Majewski M, et al. A single weekly dose of imatinib is sufficient to induce and maintain remission of chronic eosinophilic leukemia in *FIPILI/PDGFR*-expressing patients. *Br J Haematol.* 2008;141:200-204.
31. Pitini V, Arrigo C, Azzarello D, et al. Serum concentration of cardiac Troponin T in patients with hypereosinophilic syndrome treated with imatinib is predictive of adverse outcomes. *Blood.* 2003;102:3456-3457.
32. Robyn J, Noel P, Wlodarska I, et al. Imatinib-responsive hypereosinophilia in a patient with B cell ALL. *Leuk Lymphoma.* 2004;45:2497-2501.
33. Kerkela R, Grazette L, Yacobi R, et al. Cardiotoxicity of the cancer therapeutic agent imatinib mesylate. *Nat Med.* 2006;12:908-916.
34. Estabragh ZR, Knight K, Watmough SJ, et al. A prospective evaluation of cardiac function in patients with chronic myeloid leukaemia treated with imatinib. *Leuk Res.* 2011;35:49-51.
35. Gambacorti-Passerini C, Tornaghi L, Franceschino A, Piazza R, Corneo G, Pogliani E. In reply to 'Cardiotoxicity of the cancer therapeutic agent imatinib mesylate'. *Nat Med.* 2007;13(1):13-14; author reply 15-6.
36. Hatfield A, Owen S, Pilot PR. In reply to 'Cardiotoxicity of the cancer therapeutic agent imatinib mesylate'. *Nat Med.* 2007;13:13; author reply 15-16.
37. Klion AD, Robyn J, Maric I, et al. Relapse following discontinuation of imatinib mesylate therapy for *FIPILI/PDGFR*-positive chronic eosinophilic leukemia: implications for optimal dosing. *Blood.* 2007;110:3552-3556.
38. Simon D, Salemi S, Yousefi S, Simon HU. Primary resistance to imatinib in Fip1-like 1-platelet-derived growth factor receptor alpha-positive eosinophilic leukemia. *J Allergy Clin Immunol.* 2008;121:1054-1056.
39. Gotlib J, Cools J. Five years since the discovery of *FIPILI-PDGFR*: what we have learned about the fusion and other molecularly defined eosinophilias. *Leukemia.* 2008;22:1999-2010.
40. Lierman E, Michaux L, Beullens E, Pierre P, Marynen P, Cools J. *FIPILI-PDGFR*alpha D842V, a novel panresistant mutant, emerging after treatment of *FIPILI-PDGFR*alpha T674I eosinophilic leukemia with single agent sorafenib. *Leukemia.* 2009;23:845-851.
41. Ohnishi H, Kandabashi K, Maeda Y, Kawamura M, Watanabe T. Chronic eosinophilic leukaemia with *FIPILI-PDGFR* fusion and T674I mutation that evolved from langerhans cell histiocytosis with eosinophilia after chemotherapy. *Br J Haematol.* 2006;134:547-549.
42. von Bubnoff N, Sandherr M, Schlimok G, Andreesen R, Peschel C, Duyster J. Myeloid blast crisis evolving during imatinib treatment of an *FIPILI-PDGFR* alpha-positive chronic myeloproliferative disease with prominent eosinophilia. *Leukemia.* 2005;19:286-287.
43. Ikezoe T, Togitani K, Tasaka T, Nishioka C, YZokoyama A. Successful treatment of imatinib-resistant hypereosinophilic syndrome with nilotinib. *Leuk Res.* 2010;34:e200-201.
44. von Bubnoff N, Gorantla SP, Engh RA, et al. The low frequency of clinical resistance to *PDGFR* inhibitors in myeloid neoplasms with abnormalities of *PDGFR* might be related to the limited repertoire of possible *PDGFR* kinase domain mutations in vitro. *Oncogene.* 2011;30:933-943.
45. Ueno NT, Anagnostopoulos A, Rondon G, et al. Successful non-myeloablative allogeneic transplantation for treatment of idiopathic hypereosinophilic syndrome. *Br J Haematol.* 2002;119:131-134.
46. Oliver JW, Deol I, Morgan DL, Tonk VS. Chronic eosinophilic leukemia and hypereosinophilic syndromes. Proposal for classification, literature review and report of a case with a unique chromosomal abnormality. *Cancer Genet Cytogenet.* 1998;107:111-117.
47. Chang HW, Leong KH, Koh DR, Lee SH. Clonality of isolated eosinophils in the hypereosinophilic syndrome. *Blood.* 1999;93:1651-1657.
48. Luciano L, Catalano L, Sarrantonio C, Guerriero A, Califano C, Rotoli B. AlphaIFN-induced hematologic and cytogenetic remission in chronic eosinophilia leukemia with t(1;5). *Haematologica.* 1999;84:651-653.
49. Malbrain ML, Van den Bergh H, Zachee P. Further evidence for the clonal nature of the idiopathic hypereosinophilic syndrome: complete hematologic and cytogenetic remission induced by interferon-alpha in a case with a unique chromosomal abnormality. *Br J Haematol.* 1996;92:176-183.
50. Granjo E, Lima M, Lopes JM, et al. Chronic eosinophilic leukaemia presenting with erythroderma, mild eosinophilia and hyper-IgE: clinical, immunological and cytogenetic features and therapeutic approach. A case report. *Acta Haematol.* 2002;107:108-112.
51. Valent P, Akin C, Escribano L, et al. Standards and standardization in mastocytosis: consensus statements on diagnostics, treatment recommendations and response criteria. *Eur J Clin Invest.* 2007;37:435-453.
52. Garcia-Montero AC, Jara-Acevedo M, Teodosio C, et al. *KIT* mutation in mast cells and other bone marrow hematopoietic cell lineages in systemic mast cell disorders: a prospective study of the Spanish Network on Mastocytosis (REMA) in a series of 113 patients. *Blood.* 2006;108(7):2366-2372.
53. Brockow K, Jofer C, Behrendt H, Ring J. Anaphylaxis in patients with mastocytosis: a study on history, clinical features and risk factors in 120 patients. *Allergy.* 2008;63:226-232.
54. Sperr WR, Jordan JH, Fiegl M. Serum tryptase levels in patients with mastocytosis: correlation with mast cell burden and implication for defining the category of disease. *Int Arch Allergy Immunol.* 2002;128:136-141.
55. Lim KH, Tefferi A, Lasho TL, et al. Systemic mastocytosis in 342 consecutive adults: survival studies and prognostic factors. *Blood.* 2009;113:5727-5736.
56. Horny H-P, Parwaresch MR, Lennert K. Bone marrow findings in systemic mastocytosis. *Human Pathol.* 1985;16:808-814.

57. Böhm A, Födinger M, Wimazal F, et al. Eosinophilia in systemic mastocytosis: clinical and molecular correlates and prognostic significance. *J Allergy Clin Immunol*. 2007;120:191-199.
58. Lim KH, Pardanani A, Butterfield JH, Li CY, Tefferi A. Cytoreductive therapy in 108 adults with systemic mastocytosis: outcome analysis and response prediction during treatment with interferon-alpha, hydroxyurea, imatinib mesylate or 2-chlorodeoxyadenosine. *Am J Hematol*. 2009;84:790-794.
59. Ma Y, Zeng S, Metcalfe DD, et al. The *KIT* mutation causing human mastocytosis is resistant to STI571 and other *KIT* kinase inhibitors; kinases with enzymatic site mutations show different inhibitor sensitivity profiles than wild-type kinases and those with regulatory-type mutations. *Blood*. 2002;99:1741-1744.
60. Akin C, Fumo G, Yavuz AS, Lipsky PE, Neckers L, Metcalfe DD. A novel form of mastocytosis associated with a transmembrane c-kit mutation and response to imatinib. *Blood*. 2004;103:3222-3225.
61. Mital A, Piskorz A, Lewandowski K, Wasag B, Limon J, Hellman A. A case of mast cell leukaemia with exon 9 *KIT* mutation and good response to imatinib. *Eur J Haematol*. 2011;86:531-535.
62. Verstovsek S, Tefferi A, Cortes J, et al. Phase II study of dasatinib in Philadelphia chromosome-negative acute and chronic myeloid disease, including systemic mastocytosis. *Clin Cancer Res*. 2008;14:3906-3915.
63. Nakamura R, Chakrabarti S, Akin C, et al. A pilot study of nonmyeloablative allogeneic hematopoietic stem cell transplant for advanced systemic mastocytosis. *Bone Marrow Transplant*. 2006;37:353-358.